

Review of ENDOCRINOLOGY

EXAMINING THE ISSUES, TREATMENTS, AND EMERGING TRENDS IN DIABETES & ENDOCRINE DISORDERS

March 2008

FIELD Study Revealed Fenofibrate Reduced Need for Laser Treatment for Diabetic Retinopathy

By Anthony C. Keech, MBBS, Msc Epid, FRANZCS, FRACP; and
Paul Mitchell, MBBS(Hons), MD, PhD, FRANZCO, FRACS, FRCOphth, FAFPHM

This agent's mechanism of benefit in diabetic retinopathy appears to go beyond its effects on lipid concentration or blood pressure, and this potential mechanism of action operates even when glycemic control and blood pressure levels are within goal.

ABSTRACT

PURPOSE

The FIELD (Fenofibrate Intervention and Event Lowering in Diabetes) study sought to investigate whether long-term lipid-lowering therapy with fenofibrate would reduce macro- and microvascular complications among patients with type 2 diabetes. We previously reported that in type 2 diabetes patients with adequate glycemic and blood pressure control, a signif-

icant relative reduction was seen of almost one-third in the rate of first laser application for retinopathy after an average treatment duration of 5 years with fenofibrate 200 mg/day.

In this report, we detail the effects of fenofibrate administration on ophthalmic microvascular complications and attempt to clarify some of the underlying pathologies being addressed among patients undergoing laser treatment.

Jointly sponsored by The Dulaney Foundation and *Review of Endocrinology*

Jointly sponsored by The Dulaney Foundation and *Review of Endocrinology*.

Release date: March 1, 2008. Expiration date: March 1, 2009.

This continuing medical education activity is supported by an unrestricted educational grant from Abbott Laboratories.

STATEMENT OF NEED

Diabetes is becoming more common in the United States, as well as globally. Data from the Centers for Disease Control and Prevention show that from 1994 to 2004, the prevalence of diabetes increased by 80%. Type 2 diabetes accounts for 90% to 95% of all diagnosed cases of diabetes.

Diabetes is a disease of complications. But landmark studies such as the DCCT (Diabetes Control and Complication Trial) have shown that achieving tight glycemic control can directly reduce the risk of diabetic complications, especially diabetic microvascular complications. New screening tools and potential new treatments also hold promise for making diabetic microvascular complications such as retinopathy more manageable and less inevitable.

In the largest placebo-controlled clinical outcomes study ever conducted with a cholesterol-modifying medication in patients with type 2 diabetes, FIELD confirms fenofibrate produces macrovascular and microvascular benefits in diabetic patients without previous cardiovascular disease.

TARGET AUDIENCE

This activity is designed for endocrinologists, diabetologists, ophthalmologists who treat patients with diabetic eye disease, and other practitioners who focus on diabetes care.

LEARNING OBJECTIVES

Upon successfully completing this learning program, participants should be able to:

- Describe primary strategies for diabetes management that improve outcomes of diabetic retinopathy and its progression.
- Identify secondary interventions that improve outcomes of diabetic retinopathy and diabetic macular edema.
- Review the origins of pending vision loss in proliferative and non-proliferative diabetic retinopathy.
- Cite the systemic factors that affect the severity of diabetic retinopathy.
- Discuss the use of fenofibrate treatment to reduce diabetic eye disease.
- Understand the results of the FIELD study, in which the data suggest an important role of fenofibrate in preventing microvascular complications of type 2 diabetes.

METHOD OF INSTRUCTION

Participants should read the learning objectives and continuing medical education (CME) program in their entirety. After reviewing the material, they must complete the self-assessment test, which consists of a series of multiple-choice questions. To answer these questions online and receive real-time results, please visit www.dulaneyfoundation.org and click "Online Courses." If you are experiencing problems with the online test, please e-mail us at support@dulaneyfoundation.org and explain the details of any problems you encounter with the Web site. Alternatively, you can fax your exam to us at +1 610 771 4443. Please note, in order to receive your certificate and credit when faxing your test you must include your full name as well as an e-mail address, as certificates will be issued electronically. Upon completing the activity and achieving a passing score of over 70% on the self-assessment test, you may print out a CME credit letter awarding 1 AMA/PRA Category 1 Credit.[™] The estimated time to complete this activity is 1 hour.

ACCREDITATION

This activity has been planned and implemented in accordance with the Essential Areas and Policies of the Accreditation Council for Continuing Medical Education (ACCME) through the joint sponsorship of The Dulaney Foundation and *Review of Endocrinology*. The Dulaney Foundation designates this educational activity for a maximum of 1 AMA/PRA Category 1 Credit.[™] Physicians should only claim credit commensurate with the extent of their participation in the activity.

DISCLOSURE

In accordance with the disclosure policies of The Dulaney Foundation and to conform with ACCME and the US Food and Drug Administration guidelines, all program faculty are required to disclose to the activity's participants: (1) the existence of any financial interest or other relationships with the manufacturers of any commercial products/devices or providers of commercial services; and (2) the identification of a commercial product/device that is unlabeled for use or an investigational use of a product/device not yet approved.

CONTENT VALIDATION

In compliance with ACCME standards for commercial support and The Dulaney Foundation's policy and procedure for resolving conflicts of interest, this CME activity was peer reviewed for clinical content validity to ensure the activity's materials are fair, balanced and free of bias; the activity materials represent a standard of practice within the medical profession; and any studies cited in the materials upon which recommendations are based are scientifically objective and conform to research principles generally accepted by the scientific community.

FACULTY CREDENTIALS

Anthony C. Keech, MBBS, MSc Epid, FRANZCS, FRACP, is Professor of Medicine, Cardiology & Epidemiology in the Department of Medicine, School of Public Health, NHMRC Clinical Trials Centre, the University of Sydney, Australia. He may be reached at Tony@ctc.usyd.edu.au; phone: +61 2 9562 5000; or fax: +61 2 9562 5090.

Paul Mitchell, MBBS(Hons), MD, PhD, FRANZCO, FRACS, FRCOphth, FAFPHM, is a Professor in the Department of Ophthalmology at the University of Sydney, Director of Ophthalmology, Sydney West Area Health Service, Westmead Hospital, and Director, Centre for Vision Research, Westmead Millennium Institute, Westmead, Australia. He may be reached at paul_mitchell@wmi.usyd.edu.au; phone: +61 2 9845 7960; or fax: +61 2 9845 8345.

FACULTY DISCLOSURE DECLARATIONS

Prof. Keech states that he has received grant/research support and honoraria for lectures from Abbott and Solvay and is listed as an applicant on a patent application in relation to some of the findings in this report.

Prof. Mitchell states that he has nothing to disclose.

Peer reviewer William B. Trattler, MD, disclosed that has received research support from Allergan, Inc., and Ista Pharmaceuticals, Inc., and he has received honoraria for lectures and consulting from Allergan, Inc.

Additional staff who assisted with preparing this supplement, Alan Guralnick, Conni B. Koury, Erin K. Corr, and Amy Oravec, state that they have nothing to disclose.

METHODS

FIELD was a multinational, randomized, clinical trial of 9,795 patients aged 50 to 75 years who had type 2 diabetes. Included patients were randomized to 200 mg/day fenofibrate (n=4,895) or placebo (n=4,900). Upon each office visit, included patients provided information regarding laser treatment for diabetic retinopathy, a prespecified tertiary endpoint of the main study. Ophthalmologists who were masked to treatment allocation determined instances of laser treatment for macular edema, proliferative retinopathy, or other diabetic eye disease.

An ophthalmology substudy included 1,012 patients who had standardized retinal fundus photographs taken and graded according to ETDRS (Early Treatment Diabetic Retinopathy Study) criteria to determine the cumulative incidence of diabetic retinopathy and its component lesions. Analyses in this trial were by intention to treat.

FINDINGS

Laser treatment for diabetic eye disease was needed more often in participants with poor glycemic or

blood pressure control than in those with good control of these factors. Laser treatment was also needed more often in those patients with a greater burden of clinical microvascular disease. The need for treatment, however, was not affected by plasma lipid concentrations. Patients assigned treatment with fenofibrate required first laser treatment for all retinopathy significantly less often than those in the placebo group (164 [3.4%] fenofibrate-assigned patients vs 238 [4.9%] placebo-assigned patients). The hazard ratio (HR) was 0.69, with a 95% confidence interval (CI), 0.56–0.84; $P=.0002$, and there was an absolute risk reduction (RR) of 1.5% (0.7%–2.3%).

In the ophthalmology substudy, the primary endpoint of a two-step progression of retinopathy grade was not significantly different between the treatment and the placebo groups overall (46 [9.6%] patients assigned fenofibrate vs 57 [12.3%] assigned placebo; $P=.19$) or in the cohort of patients who did not have preexisting diabetic retinopathy (43 [11.4%] vs 43 [11.7%]; $P=.87$). Among patients with preexisting retinopathy, however, significantly fewer

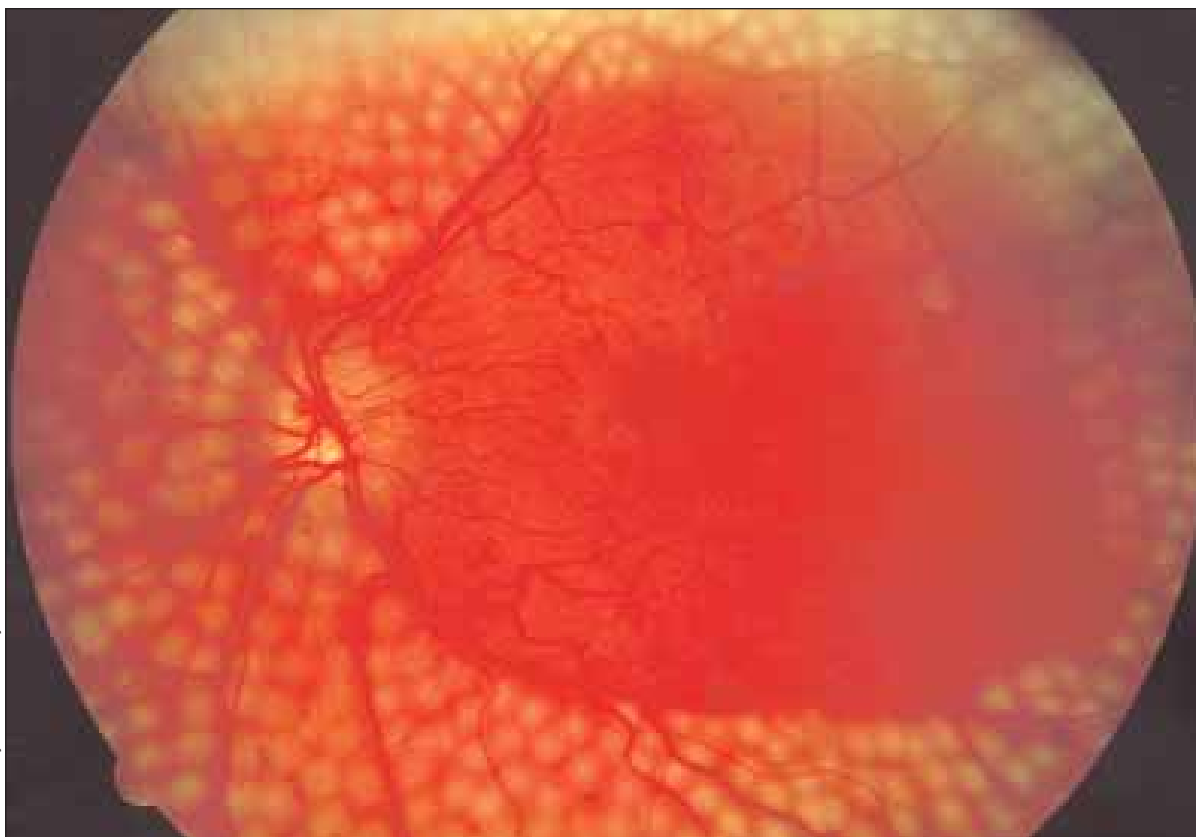


Photo courtesy of the National Eye Institute

Figure 1. Fundus photograph showing extensive scatter laser surgery for diabetic retinopathy.

who were assigned fenofibrate had a two-step progression than did those in the placebo group (three [3.1%] patients vs 14 [14.6%]; $P=.004$).

An additional, exploratory composite endpoint of two-step progression of retinopathy grade, macular edema, or laser treatments was significantly lower in the fenofibrate group versus placebo-assigned patients (HR 0.66, 95% CI 0.47–0.94; $P=.022$).

CONCLUSION

Fenofibrate treatment among patients with type 2 diabetes reduced the need for laser treatment for diabetic eye disease. The mechanism by which this happens remains unclear, however, it does not appear to be related to plasma lipid concentrations.

BACKGROUND

More than 135 million people worldwide are currently afflicted with diabetes, more than 18.2 million in the United States alone. Diabetic retinopathy is the most common microvascular complication of diabetes, it is the leading cause of vision loss and blindness in working age adults and causes 10,000

people to go blind every year.^{1,2} This fact is made even more sobering by statistics showing that type 2 diabetes prevalence is rapidly increasing worldwide.

Patients with diabetic retinopathy lose vision mainly from central macular edema but also to some extent from proliferative diabetic retinopathy. Diabetic retinopathy is characterized by vasodilation and hyperperfusion that leads to capillary loss and ischemia. These patients experience protein and fluid leakage from the damaged capillaries, which in turn causes macular edema and the accumulation of lipid and protein deposits or hard exudates. These pathological changes are related to prolonged exposure to the hyperglycemic state.^{3,4}

Clinical trials have shown that laser photocoagulation for the treatment of leaking microaneurysms can slow or prevent further vision loss in diabetic retinopathy (Figures 1 and 2).^{2,5,6} But laser treatment is often associated with visual field reduction and ocular side effects,⁷ so an alternative that could potentially reduce the need for its use would be an important advance in the management of diabetic retinopathy.

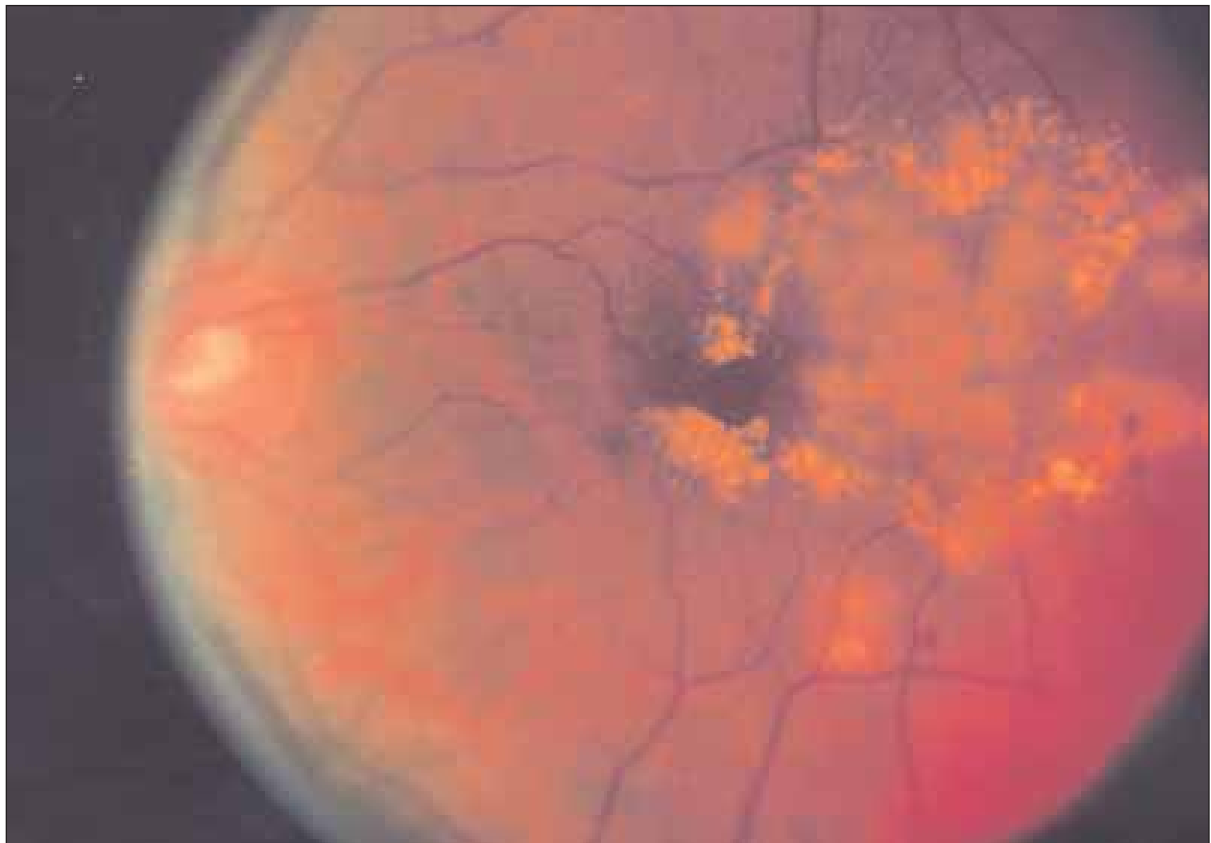

Photo courtesy of the National Eye Institute

Figure 2. Fundus photo showing focal laser surgery for diabetic retinopathy.

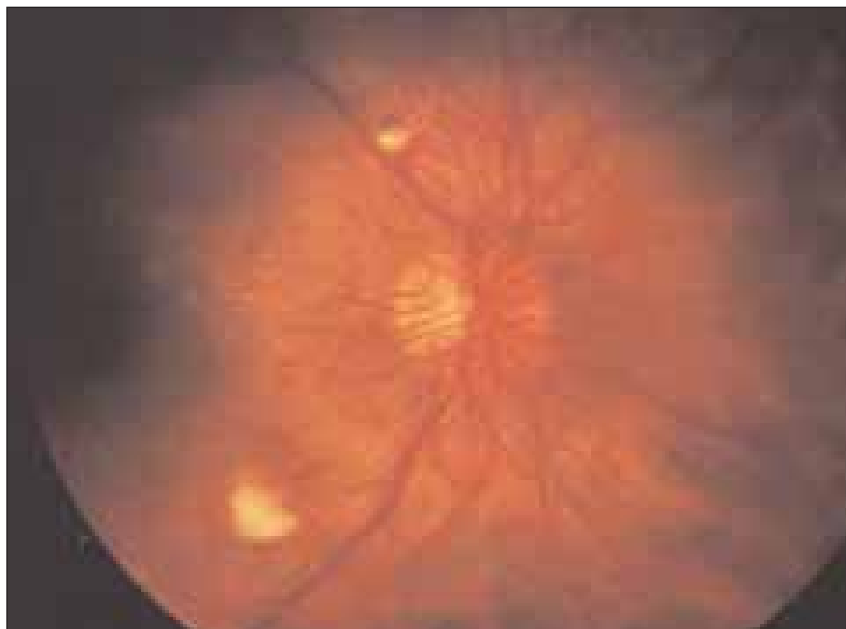

Figure 3. Proliferative retinopathy, an advanced form of diabetic retinopathy, occurs when abnormal new blood vessels and scar tissue form on the surface of the retina.

It is known that medical management of risk factors associated with diabetic retinopathy helps to slow retinal disease progression.⁸⁻¹⁰ There is a clear association between diabetic retinopathy and glycemia, diabetes duration, hypertension, and microalbuminuria; however, control of these factors does not completely prevent disease or progression.

Previous work has pointed to a link between lipid levels, the development and severity of diabetic retinopathy, the development and severity of proliferative diabetic retinopathy, hard exudates, and macular edema¹¹⁻²⁰ (Figures 3 and 4). Although the benefits of lipid-lowering therapy on the management of diabetic retinopathy have not been well elucidated thus far.^{21,22} It is clear that the potential for benefit exists. Additionally, although statins have proven unsuccessful for the prevention of diabetic retinopathy,²³ previous studies with peroxisome proliferator-activated receptor (PPAR)-alpha agonists—fibrates—have found beneficial effects.²⁴⁻²⁹

Therefore, the FIELD study sought to assess whether long-term lipid-lowering therapy with fenofibrate could reduce macro- and microvascular outcomes in patients with type 2 diabetes. In 2005, we published our findings: In type 2 diabetes patients with adequate glycemic and blood pressure control, there was a significant relative reduction of about one-third in the rate of first laser treatment

for retinopathy after an average of 5 years' treatment of 200/mg day fenofibrate.³⁰

STUDY DETAILS INCLUSION AND EXCLUSION CRITERIA

Included in FIELD were patients aged 50 to 75 years with type 2 diabetes and an initial total cholesterol level of 3.0 to 6.5 mmol/L and a total cholesterol/HDL ratio of ≥ 4.0 , or a triglyceride level of 1.0 to 5.0 mmol/L, without requiring lipid-modifying agents upon entry into the study.

Excluded patients included those with significant renal impairment, chronic liver disease, symptomatic gall-

bladder disease, or a cardiovascular event within the 3 months prior to study recruitment.^{30,31}

TREATMENT, METHODS, AND PROCEDURES

The 9,795 patients eligible for inclusion in FIELD were randomized to micronized fenofibrate 200 mg/day or placebo. The scheduled study visits occurred at 4- to 6-month intervals over 5 years in conjunction with usual care by the patients' health care providers. We gathered baseline information with regard to retinopathy history, however, retinal photographs of the patients were not routinely taken in the main study. Instances of and documentation

Because laser treatment remained up to the discretion of the patients' usual doctors, we believe that the use in the trial reflected typical clinical practice.

for laser photocoagulation treatment for diabetic retinopathy were recorded at every visit. The occurrence of laser treatment for retinopathy was a pre-specified tertiary endpoint of the main FIELD study. It is important to note, however, that there were no constraints with respect to the study protocol regard-

ing the use of laser for diabetic retinopathy treatment. Therefore, laser treatment remained up to the discretion of the patients' usual doctors. We believe that, as such, laser use in FIELD reflected "real-world" clinical practice.

Documentation of laser use was verified while investigators remained masked to the treatment groups. At least two FIELD ophthalmologists ascertained the reason for each laser treatment episode. New laser treatments were recorded when the date of laser treatment was at least 10 weeks after the previously reported course of treatment. Treatment was classified as being for macular edema or proliferative retinopathy without macular involvement. Laser treatments identified as being for the resolution of capsular opacity, iridotomy, retinal breaks, or other nondiabetic eye conditions, were excluded from the analysis.

OPHTHALMOLOGY SUBSTUDY

At 22 of the 63 FIELD sites, patients were asked to participate in an ophthalmic study involving serial

retinal fundus photography. Those who were eligible for inclusion had two-field color fundus photos of both eyes that showed no evidence of proliferative retinopathy, severe nonproliferative retinopathy, clinically significant macular edema, or indication for or evidence of a history of laser treatment at a screening exam during the placebo run-in phase.

Status and severity of retinopathy were assessed from two-field 45° color fundus photos at baseline, 2 years, 5 years, and at the end of the study as part of FIELD follow-up. Investigators were looking for long-term changes in diabetic retinopathy status and any possible treatment effects. Grading was done by ophthalmologists according to ETDRS criteria.^{5,32}

Retinal photos were taken of two fields in both eyes in accordance with EURODIAB guidelines. Macular edema was characterized by the presence of the thickening of the retina. Clinically significant macular edema was defined as having one of the following three criteria: (1) retinal thickening at or within 500 μm of the center of the macula associat-

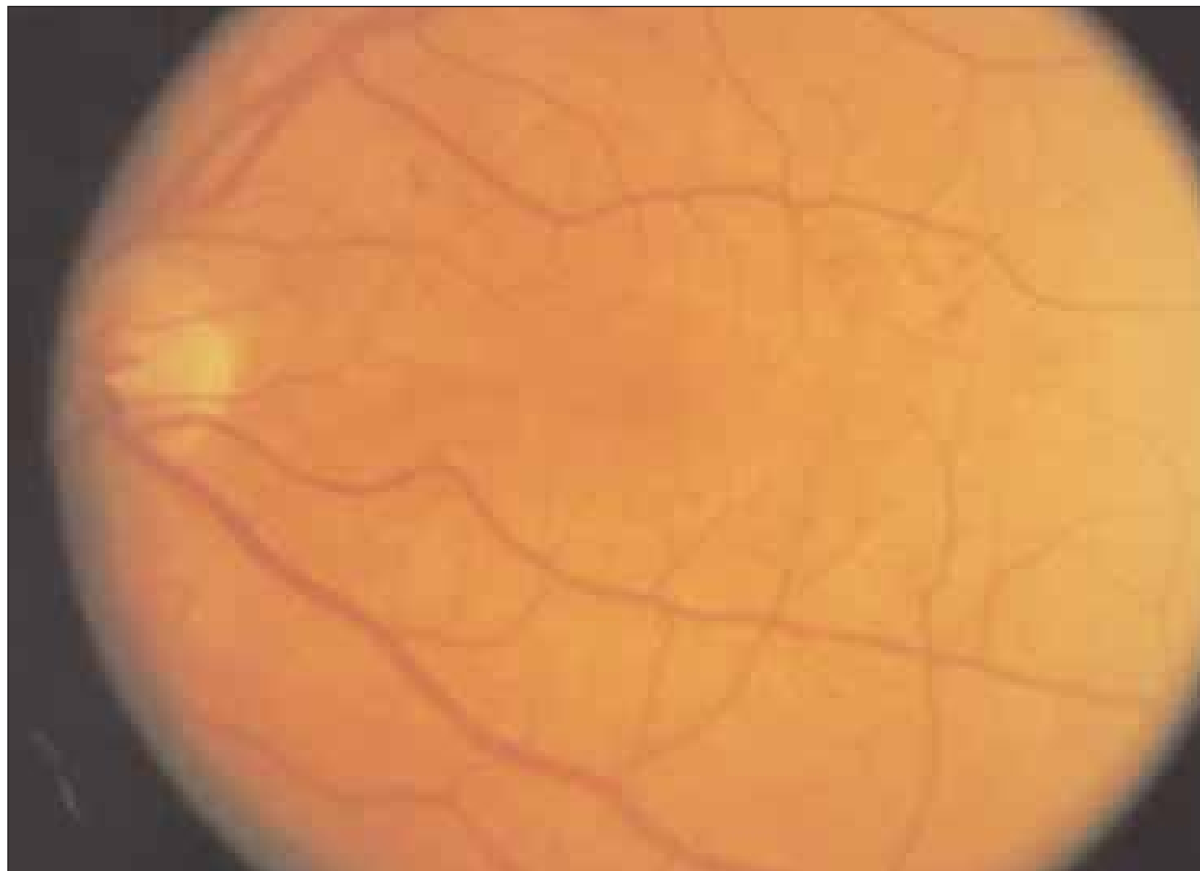


Photo courtesy of the National Eye Institute

Figure 4. In background retinopathy, a slight deterioration in the small blood vessels of the retina, portions of the vessels may swell and leak fluid into the surrounding retinal tissue.

TABLE 1. BASELINE CHARACTERISTICS OF PARTICIPANTS REQUIRING OR NOT REQUIRING LASER TREATMENT DURING THE STUDY

	No Laser Treatment (n=9,393)	Laser Treatment (n=402)	P Value
General Characteristics			
Gender (male)	5,864 (62.4%)	274 (68.2%)	.020
Ethnic origin (white)	8,728 (92.9%)	365 (90.8%)	.106
Age at visit 1 (years)	62.3 (6.9)	61.5 (6.7)	.032
Diabetes duration (years)	5.0 (2.0–9.0)	12.0 (8.0–16.0)	<.0001
BMI (kg/m ²)	29.8 (26.8–33.5)	29.6 (27.0–33.4)	.868
Waist–hip ratio	0.94 (0.88–0.98)	0.95 (0.91–1.00)	<.0001
Systolic blood pressure (mm Hg)	140.3 (15.3)	144.9 (16.2)	<.0001
Diastolic blood pressure (mm Hg)	82.0 (8.5)	83.0 (9.5)	.024
Current smoker	892 (9.5%)	30 (7.5%)	.171
Ex-smoker	4,747 (50.5%)	197 (49.0%)	.547
Clinical history			
Previous CVD	2,036 (21.7%)	95 (23.6%)	.352
Myocardial infarction	466 (5.0%)	19 (4.7%)	.832
Stroke	324 (3.4%)	23 (5.7%)	.016
Angina	1,136 (12.1%)	51 (12.7%)	.722
Peripheral vascular disease	670 (7.1%)	42 (10.4%)	.012
Coronary revascularization (CABG or PTCA)	348 (3.7%)	15 (3.7%)	.978
History of hypertension	5,329 (56.7%)	217 (54.0%)	.275
Any microvascular disease	1,767 (18.8%)	258 (64.2%)	<.0001
Diabetic retinopathy	614 (6.5%)	200 (49.8%)	<.0001
Diabetic neuropathy	1,238 (13.2%)	157 (39.1%)	<.0001
Diabetic nephropathy	243 (2.6%)	36 (9.0%)	<.0001
Laboratory data			
Total cholesterol (mmol/L)	5.04 (0.70)	5.04 (0.69)	.862
LDL cholesterol (mmol/L)	3.07 (0.65)	3.07 (0.68)	.847
HDL cholesterol (mmol/L)	1.10 (0.26)	1.10 (0.27)	.689
Triglyceride (mmol/L)	1.74 (1.34–2.33)	1.71 (1.33–2.27)	.642
Fasting glucose (mmol/L)	8.4 (7.0–10.2)	11.0 (8.9–13.0)	<.0001
A1C (%)	6.8% (6.1–7.7)	8.3% (7.2–9.4)	<.0001
Creatinine (μmol/L)	77.6 (15.8)	77.3 (16.5)	.720
Homocysteine (μmol/L)	9.5 (8.0–11.5)	10.1 (8.3–12.4)	.0001
Dyslipidemia	3569 (38.0%)	141 (35.1%)	.237
Microalbuminuria	1,727 (18.4%)	123 (30.6%)	<.0001
Macroalbuminuria	257 (2.7%)	56 (13.9%)	<.0001
Baseline cardiovascular medication			
Antithrombotic	2,923 (31.1%)	145 (36.1%)	.036
Aspirin	2,695 (28.7%)	134 (33.3%)	.044
Antithrombotic (excluding aspirin)	292 (3.1%)	16 (4.0%)	.327
Angiotensin-converting enzyme inhibitors	3,127 (33.3%)	154 (38.3%)	.037
Angiotensin II receptor antagonist	504 (5.4%)	18 (4.5%)	.438
Beta-blocker	1,368 (14.6%)	54 (13.4%)	.528
Calcium antagonist	1,813 (19.3%)	79 (19.7%)	0.862
Nitrate	525 (5.6%)	25 (6.2%)	.591
Diuretic	1,424 (15.2%)	61 (15.2%)	.994
Baseline blood-glucose-lowering medication			
Diet alone	2,602 (28.1%)	6 (1.7%)	.0001
Metformin alone	1,699 (18.1%)	22 (5.5%)	<.0001
Sulfonylurea alone	1,568 (16.7%)	43 (10.7%)	.001
Metformin plus sulfonylurea	2,173 (23.1%)	147 (36.6%)	<.0001
Other oral agent	19 (0.2%)	0 (0.0%)	.367
Metformin and/or sulfonylurea + other agent	155 (1.7%)	15 (3.7%)	.002
Insulin alone	529 (5.6%)	78 (19.4%)	.0001
Insulin plus oral agent	648 (6.9%)	91 (22.6%)	<.0001

Data are n (%) mean (SD), or median (IQR). BMI = body mass index; CABG = coronary artery bypass graft surgery; PTCA = percutaneous transluminal coronary angioplasty. From Lancet. 2007;370:1687–1697.

ed with macular edema; (2) hard exudates at or within 500 μm of the center of the macula associated with macular edema; and (3) zones of retinal thickening at least 1 disc area in size, any part of which was within 1 disc diameter of the center of the macula.⁶

Macular edema was considered to be absent, present but not clinically significant (not involving the foveal center), or present and clinically significant (involving the foveal center). Additionally, hard exudates were graded as absent or present, and when present, were graded by comparison with modified ETDRS (Figure 5).

OBJECTIVES AND STUDY QUESTIONS

The FIELD substudy’s main objective was to determine treatment effects on diabetic retinopathy progression. We defined this as at least a two-step increase in ETDRS grade after ≥2 years’ follow-up for all patients. In a further subclassification: (1) secondary—a two-step progression of existing retinopathy in those with a baseline grade of ≥20 and (2) primary—a two-step progression of retinopathy in those with a baseline grade of ≤15.

A one-step progression, the occurrence or progression of macular edema, hard exudates, and the occurrence of laser treatment, vitrectomy, and cataract, and deterioration of visual acuity by two lines (Snellen) were all considered as secondary endpoints.

Development of new retinopathy was defined as grade ≥20 in ETDRS after ≥2 years’ follow-up in patients with grade ≤15 at baseline. We employed a post hoc exploratory composite endpoint to reflect the development of significant retinal pathology, which included a two-step progression of retinopathy grade, new macular edema, or laser treatment.

All statistical analyses were done on an intention-to-treat basis. Cox proportional hazard analysis was used to compute HRs and 95% CI to assess the effect of fenofibrate on the time to first laser treatment event.

STUDY FINDINGS AND RESULTS

The 9,795 patients in FIELD were randomized into two groups, 4,895 of whom were assigned to fenofibrate and 4,900 assigned to matching placebo. A total of 8.3% of patients (412 placebo; 402 treatment) reported having a history of retinopathy before joining

the study. The remaining 91.7% reported no such history of retinopathy. The treatment and placebo groups were well matched in terms of baseline characteristics.³⁰ More than 99% of patients who were alive at study end were followed up.

A total of 402 patients (4.1%) underwent one or more laser treatments for diabetic retinopathy during follow-up. Nearly half of the patients who required laser treatment during the study required several courses. There was a dramatic difference between the baseline characteristics and medications of those patients who did and did not require

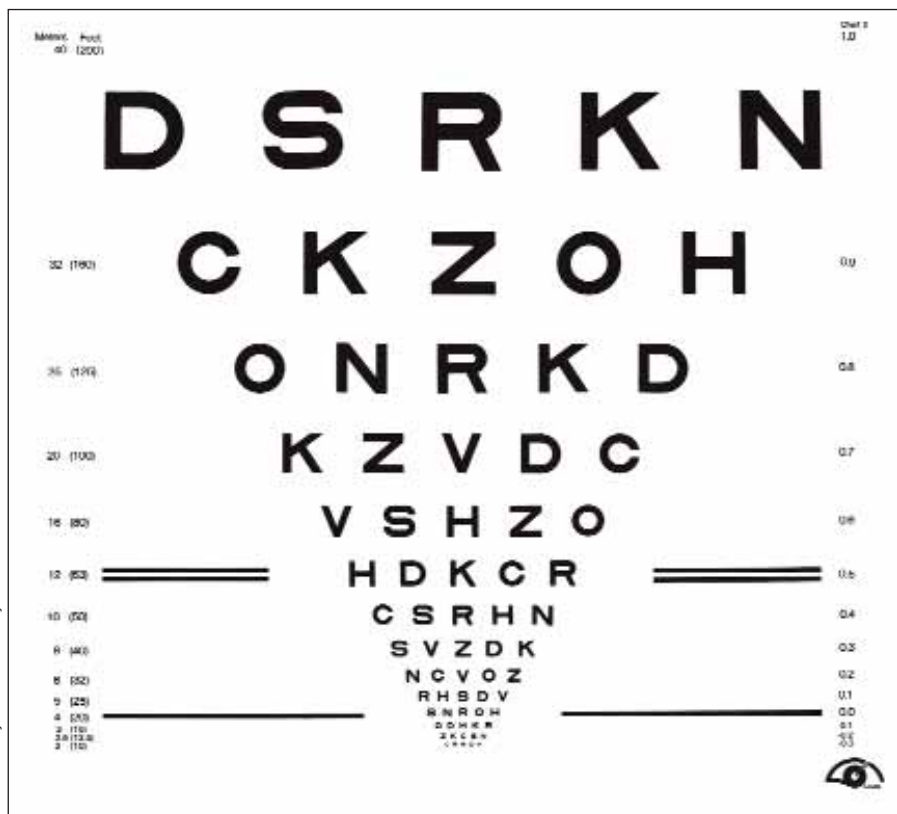


Figure 5. ETDRS (Early Treatment of Diabetic Retinopathy Study) visual acuity chart.

Photo courtesy of the National Eye Institute

TABLE 2. STAGE OF DIABETIC RETINOPATHY (ETDRS GRADING) AT BASELINE OF THE WORSE EYE IN PATIENTS NEEDING LASER TREATMENT IN THE OPHTHALMOLOGY SUBSTUDY

	ETDRS Grading	Placebo: Number Needing Laser Treatment/Number in Group (%)*	Fenofibrate: Number Needing Laser Treatment/Number in Group (%)*
Absent	10	1/357 (0.28%)	1/363 (0.28%)
Questionable	14 and 15	1/40 (2.5%)	0/44 (0%)
Minimal, nonproliferative	20	3/52 (5.8%)	0/41 (0%)
Mild, nonproliferative	35	4/26 (15.3%)	2/47 (4.3%)
Moderate, nonproliferative	43	10/21 (47.6%)	1/14 (7.1%)
Moderately severe, nonproliferative, or worse	47–99	4/4 (100%)	1/3 (33.3%)
Total		23/500 (4.6%)	5/512 [†] (1.0%)

**Each percentage expresses the number of patients needing laser treatment as a proportion of the total number with that ETDRS grade of retinopathy at baseline.*

[†]Fewer first instances of laser treatment in those allocated to fenofibrate than in those allocated to placebo, P=.0004. From Lancet. 2007;370:1687-1697.

laser treatment (Table 1).

Specifically, patients who received laser were more likely to be male, had a 7-year longer duration of diabetes, a slightly higher waist-to-hip ratio, close to a 5 mm Hg higher average systolic blood pressure, and were more likely to have had a stroke or a peripheral vascular event when compared with those patients who did not need laser treatment. The patients who needed laser treatment were also sicker; they were more likely to report prior microvascular complications, such as retinopathy, neuropathy, and nephropathy at baseline. Other parameters of diabetes and metabolic control such as fasting plasma glucose, A1C levels, homocysteine, and measured levels of micro- or macroalbuminuria, were worse in the patients who needed laser treatment.

Perhaps surprisingly, however, no differences were seen in baseline concentrations of lipids, including total cholesterol, HDL, and calculated LDL.

RESULTS

Of the total 872 courses of laser in FIELD among 402 patients, most were determined to be for macular edema alone or macular edema in combination with proliferative retinopathy (61% of first treat-

ments). The remaining treatments were for proliferative retinopathy with no macular involvement. Baseline lipid levels were not different among these groups.

The fenofibrate-assigned patients had a significantly lower rate of requiring first laser treatment for any retinopathy than did patients in the placebo group (164 or 3.4% fenofibrate vs 238 or 4.9% placebo; HR 0.69; 95% CI, 0.56–0.84; P=.0002), an absolute RR of 1.5%. The relative RRs were similar for patients requiring any first laser therapy for maculopathy or for proliferative retinopathy. The size of the effect remained almost unchanged when adjusted for baseline characteristics that predicted the need for laser treatment. Separation of the cumulative incidence curves was observed at about 8 months into treatment; the benefits were greater with time.

Fenofibrate's relative effects appeared to be greater in those without than with a history of retinopathy, although this difference was not statistically significant. Over a 5-year period, the risk of needing a first laser treatment in patients assigned placebo in FIELD was about 3% among patients with no history of retinopathy and 27% in those with such a history. Thus the absolute RR was much greater among patients with a history of retinopa-

thy. In other words, if treated with fenofibrate, there would be 5.8 fewer first laser treatments per 100 patients (number needed to treat [NNT] 17) among those with a history of the disease versus 1.1 fewer in those without a history of the disease (NNT 90).

A total of 872 laser courses were given; 535 to 238 patients assigned placebo (4.9%) and 337 to 164 fenofibrate-assigned patients (3.4%). This translates into a relative reduction with fenofibrate of 37%, 95% CI, 19–51; $P=.0003$. There was a relative reduction in the need for laser treatment of 36% (95% CI, 14–52; $P=.003$) among patients assigned fenofibrate for any maculopathy and 38% (95% CI, 11–57; $P=.009$) for proliferative retinopathy.

SAFETY

Not much difference in the safety profile of fenofibrate and placebo was seen over the 5-year follow-up. A small increase in the rare clinical events of pancreatitis and pulmonary embolism was observed,³⁰ and increases in creatinine and homocysteine were seen soon after active treatment began, but these levels reversed over 6 to 8 weeks following drug withdrawal.³⁰

OPHTHALMOLOGY SUBSTUDY

Patients from 22 centers were recruited for the ophthalmology substudy (1,012 patients, 10.3% of the study population). These patients matched the overall cohort in terms of baseline characteristics. Of note, these patients had a slightly lower rate of previous cardiovascular disease and less of a history of retinopathy. Of this subgroup, 850 (421 assigned placebo, 429 fenofibrate) were followed to the end of the study.

About 80% of the patients in the ophthalmology substudy had no or questionable diabetic retinopathy at baseline and a low risk for laser treatment. The risk of needing laser therapy increased with increasing baseline ETDRS retinopathy grades (Table 2). There were 28 patients in the substudy who required first laser treatment, most had minimal-to-moderately severe nonproliferative diabetic retinopathy. The status of drug treatments among the patients in the substudy was either similar or greater in placebo-assigned patients than in fenofibrate-assigned patients by the study's end.

Two-step progression of retinopathy grade—the primary endpoint—was not significantly different between the two groups; however, among patients

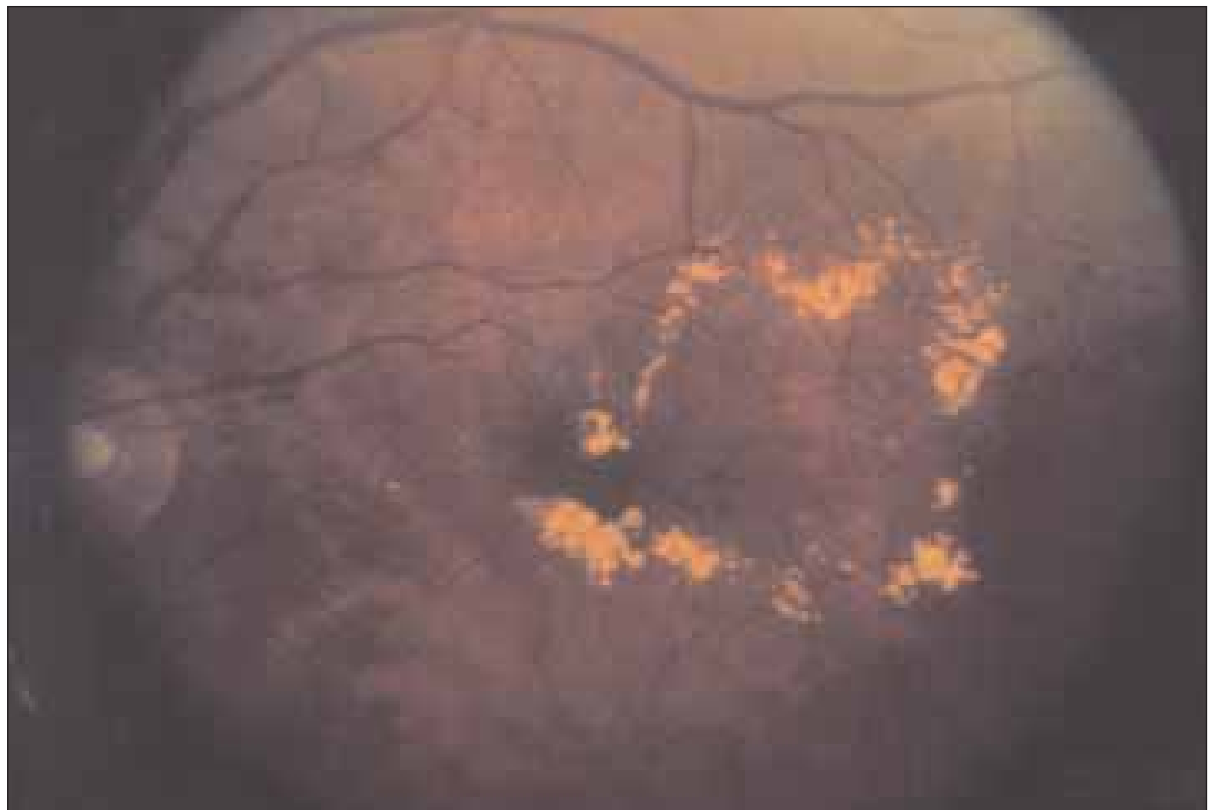

Photo courtesy of the National Eye Institute

Figure 6. Diabetic macular edema.

who had preexisting retinopathy, significantly fewer patients assigned fenofibrate had a two-step progression than did those assigned placebo. By way of contrast, the number of patients without preexisting retinopathy who had a two-step progression was similar in the two groups. Therefore, the treatment effect was significantly different within these two subgroups.

DISCUSSION

We found that fenofibrate treatment—in addition to established risk factor management—reduced the need for first laser treatment for diabetic retinopathy in type 2 diabetes patients. The reduction was mainly found in a lower prevalence of macular edema (Figure 6) as the underlying cause of diabetic retinopathy in this study. There were reductions in proliferative diabetic retinopathy treatment without macular involvement as well. Further supporting these findings are data from the ophthalmology substudy in which we found less progression of preexisting retinopathy in patients treated with fenofibrate and a suggestion of less macular edema.

The frequency of the exploratory composite endpoint of progression, macular edema, or laser treatment was about one-third lower among fenofibrate-assigned patients versus the placebo group. Of particular note in the substudy, the benefit was largely seen in patients with preexisting retinopathy, and there was not a significant drop in two-step progression of retinopathy grade in patients without preexisting disease.

A somewhat greater reduction in the relative risk of laser treatment was seen when all laser treatment events were assessed, suggesting that there is a continuing benefit beyond the first laser treatment. Perhaps the most striking result was how quickly fenofibrate therapy showed a benefit, with a divergence in the need for laser evident at about 8 months of treatment allocation. Although a reduction in the relative risk of laser treatment with fenofibrate seemed to be more pronounced in patients without a history of diabetic eye disease, this might have been due to previously undiagnosed retinopathy in many of the patients.

WHAT IS HAPPENING?

The mechanism by which fenofibrate achieved its effects in this trial are unclear. Fenofibrate is a lipid-modifying agent, and after 4 months of treatment patients had total cholesterol reduced by 11%, LDL

by 12%, and triglycerides by 29%; HDL increased by 5%.³⁰ This effect on lipids was attenuated over time, however, and there was no clinically important difference in HDL at study completion between the treatment and placebo groups.³⁰

Although the requirement over a 5-year period for laser treatment was strongly associated with higher baseline fasting glucose and A1C, fenofibrate did not improve these markers of diabetes control.³⁰ Fenofibrate did lower blood pressure, which is strongly associated with laser treatment,³³ but probably not enough to explain these findings. Also, consider that the improvements occurred in more than 60% of patients who were already receiving treatment with angiotensin-converting enzyme inhibitors or angiotensin II antagonists.

The mechanism of action of fenofibrate may be related to PPAR-alpha agonists' ability to inhibit the vascular endothelial growth factor pathway.

WHAT DOES IT MEAN?

Our findings suggest that the mechanism of benefit of this agent in diabetic retinopathy goes beyond its effects on lipid concentration or blood pressure, and this potential mechanism of action operates even when lipid levels are controlled effectively with statin therapy and antihypertensive treatment is working.

Microvascular ischemia with vascular leakage is the hallmark of diabetic retinopathy, however macular edema is the most frequent cause of visual loss.³⁴ The mechanism of action of fenofibrate, although not yet totally elucidated, may be related to PPAR-alpha agonists' ability to inhibit the vascular endothelial growth factor (VEGF) pathway, which is crucial to the cascade of events including angiogenesis, inflammation, and cell migration,³⁵ all of which have a potential role in diabetic retinopathy.

Fenofibrate has been shown to regulate retinal endothelial cell survival and prevent apoptotic cell death.³⁶ It is also known to stimulate expression of VEGF mRNA in the retina via the AMP-activated protein kinase signal transduction pathway. Early on in the development of diabetic retinopathy, VEGF expression may be increased to help stabilize the

QUALITY OF LIFE AND DIABETIC EYE DISEASE

Visual impairment has been shown to adversely affect the health-related quality of life (HRQOL) in people with diabetic retinopathy.¹⁻⁵ In fact, research has shown that patients with diabetic retinopathy report a higher incidence of visual problems than those with age-related macular degeneration, cataracts, cytomegalovirus retinitis, and low vision from any cause. Wuslin et al⁶ evaluated the psychological effects of diabetic retinopathy and its resulting visual impairment and found that there were moderate correlations between visual acuity and worsening psychological symptoms, in a cohort of patients with proliferative diabetic retinopathy. Another study by Bernbaum et al⁷ found that, compared with diabetic retinopathy patients who had stable visual impairment, those with fluctuating visual impairment experienced greater emotional distress and depression.

Coyne et al⁸ conducted exploratory qualitative research to evaluate the symptom experience of diabetic retinopathy, its impact on activities of daily living and HRQOL, as well as the applicability of two vision-specific questionnaires (Visual Function 14-Item Scale [VF-14] and the National Eye Institute-Visual Function Questionnaire 25 [NEI-VFQ-25]). The investigators conducted four focus groups, each with 15 participants who were adults with type 1 or 2 diabetes and mild, moderate, or severe nonproliferative diabetic retinopathy or proliferative diabetic retinopathy. The participants described a range of symptoms and impact, specifically, difficulty driving and trouble reading were noted with all levels of severity. Patients who were suffering from proliferative diabetic retinopathy and decreased visual acuity said that they had stopped taking part in many important aspects of their lives, such as work, reading, and sports. Additionally, among those with more severe diabetic eye disease, even caring for their diabetes was severely affected (eg, exercising, reading nutritional labels, preparing insulin injections, and glucose testing).

The participants also expressed that the loss of independence, especially because of mobility issues and increased fear of accidents had a profound impact on their social activities.

Coyne and colleagues concluded that the loss of independence and mobility associated with decreased visual functioning and visual loss were major concerns. Moderate, severe nonproliferative diabetic retinopathy, and proliferative diabetic retinopathy associated with visual impairment have a significant impact on HRQOL, particularly in the areas of independence, mobility, leisure, and self-care activities.

In Coyne's report, they also said that diabetic retinopathy patients differ from other patients with ophthalmological conditions that cause visual impairment because they have an underlying chronic condition of which diabetic retinopathy is a complication.

"Diabetes, independent of diabetic retinopathy, has been shown to have a negative impact on HRQOL,⁹ and the addition of diabetic retinopathy with its negative consequences may exacerbate this effect, resulting in further HRQOL decrements," they wrote. "Certainly, controlling diabetes is more challenging for some diabetic retinopathy patients due to the inability to read labels, exercise, test glucose levels, or even administer insulin. This additional challenge complicates maintaining adequate glycemic control, which can further impair vision and also increase the likelihood of suffering from other diabetic complications. Interestingly, almost half of the participants were able to correlate visual changes with glucose levels, as evidenced by comments such as, 'I knew that when my vision started to get distorted, my sugar was too high,' and 'I know when I'm lax, and my blood sugar is elevated, I get blurriness.' "

1. Mangione CM, Lee PP, Pitts J, Gutierrez P, Berry S, Hays RD. Psychometric properties of the National Eye Institute Visual Function Questionnaire (NEI-VFQ). *Arch Ophthalmol*. 1998;116:1496-1504.

2. Boisjoly H, Gresset J, Fontaine N et al. The VF-14 index of functional visual impairment in candidates for a corneal graft. *Am J Ophthalmol*. 1999;128:38-44.

3. Klein R, Moss SE, Klein BEK, Guitierrez P, Mangione CM. The NEI-VFQ-25 in people with long term type 1 diabetes mellitus. The Wisconsin Epidemiologic Study of Diabetic Retinopathy. *Arch Ophthalmol*. 2001;119:733-740.

4. Musch DC, Farjo AA, Meyer RF, Waldo MN, Janz NK. Assessment of health-related quality of life after corneal transplantation. *Am J Ophthalmol*. 1997;124:1-8.

5. Scott IU, Schein OD, West S, Bandeen-Roche K, Enger C, Folstein MF. Functional status and quality of life measurement among ophthalmic patients. *Arch Ophthalmol*. 1994; 112:329-335.

6. Wuslin LR, Jacobson AM, Rand LI. Psychosocial aspects of diabetic retinopathy. *Diabetes Care*. 1987;10:367-373.

7. Bernbaum M, Albert SG, Duckro PN. Psychosocial profiles in patients with visual impairment due to diabetic retinopathy. *Diabetes Care*. 1988;11:551-557.

8. Coyne KS, Margolis MK, Kennedy-Martin T, et al. The impact of diabetic retinopathy: perspectives from patient focus groups. *Family Practice*. 2004;21:447-453.

endothelial vascular bed.³⁷ Because fenofibrate has also been shown to improve endothelial-dependent vascular reactivity,³⁷ fenofibrate may prevent the need for laser treatment in diabetic retinopathy by inhibiting apoptosis of retinal endothelial cells, preventing cell migration, and reducing inflammation.

Inflammation may play a role in diabetic retinopathy. For example, the concentration of the RANTES cytokine is elevated among patients with severe nonproliferative diabetic retinopathy, compared with those who have less severe disease.³⁸

Fenofibrate was shown to lower intercellular adhesion molecule 1 (ICAM-1), which is upregulated in diabetic retinopathy.^{38,39}

Proinflammatory cytokines interleukin-1 beta and tumor necrosis factor-alpha are probably elevated in the serum and the vitreous of patients with diabetic retinopathy when compared with healthy patients.⁴⁰ Fenofibrate has been shown to reduce these markers as well as others of endothelial dysfunction.⁴¹

Additionally, fenofibrate may also have a protective effect on the progression of diabetic retinopathy by inhibiting oxidative stress.

Fenofibrate may also have a protective effect on the progression of diabetic retinopathy by inhibiting oxidative stress.

SUMMARY AND RECOMMENDATIONS

Fenofibrate treatment in the FIELD study demonstrated a clear reduction in the need for laser treatment, as well as a possible reduction in the development of macular edema, among patients with type 2 diabetes. It is important to note how critical these findings are in the context of the global burden of type 2 diabetes worldwide.⁴² (See accompanying sidebar, *Quality of Life and Diabetic Eye Disease*.) The described data also come on the heels of disappointing results with other medical treatments for diabetic retinopathy management.^{33,43-46}

We believe that fenofibrate may have antiapoptotic, antiinflammatory, and antioxidative effects and might also improve vascular reactivity, thus attenuating diabetic retinopathy and lessening the need for laser treatment. Continued investigation of FIELD patients with respect to oxidative stress and

vascular inflammation will assist in answering these questions more completely.

CONCLUSION

Fenofibrate's benefit was substantial in the FIELD study regarding the need for laser treatment for retinopathy in patients with type 2 diabetes. These benefits are likely to be additive to those gained from tight glucose and blood pressure control in the management of type 2 diabetes, and the benefits emerge rapidly after the onset of therapy. Because of its benefits in retinal disease, fenofibrate should be considered in the management of diabetic eye disease. ■

Conni B. Koury, editor in chief of Review of Endocrinology, provided editorial assistance for this supplement.

REFERENCES

1. Porta M, Allione A. Current approaches and perspectives in the medical treatment of diabetic retinopathy. *Pharmacol Ther*. 2004;103:167-177.
2. Neubauer AS, Uilbig MW. Laser treatment in diabetic retinopathy. *Ophthalmologica*. 2007;221:95-102.
3. UKPDS Group. Intensive blood-glucose control with sulphonylureas or insulin compared with conventional treatment and risk of complications in patients with type 2 diabetes (UKPDS 33). *Lancet*. 1998;352:837-853.
4. Stratton IM, Kohner EM, Aldington SJ, et al. UKPDS 50: risk factors for incidence and progression of retinopathy in type II diabetes over 6 years from diagnosis. *Diabetologia*. 2001;44:156-163.
5. ETDRS Group. Early photocoagulation for diabetic retinopathy. ETDRS report number 9. *Ophthalmology*. 1991;98:766-785.
6. ETDRS Group. Photocoagulation for diabetic macular edema. ETDRS report number 1. *Arch Ophthalmol*. 1985;103:1796-1806.
7. Aiello LM. Perspectives on diabetic retinopathy. *Am J Ophthalmol*. 2003;136:122-135.
8. Fong DS, Aiello LM, Ferris FL, Klein R. Diabetic retinopathy. *Diabetes Care*. 2004;27:2540-2553.
9. DCCT Group. The absence of a glycemic threshold for the development of long-term complications: the perspective of the Diabetic Control and Complications Trial. *Diabetes*. 1996;45:1289-1298.
10. UKPDS Group. Tight blood pressure control and risk of macrovascular and microvascular complications in type 2 diabetes. *BMJ*. 1998;317:703-713.
11. Chew EY, Klein ML, Ferris FL, et al. Association of elevated serum lipid levels with retinal hard exudate in diabetic retinopathy. Early Treatment Diabetic Retinopathy Study (ETDRS) Report 22. *Arch Ophthalmol*. 1996;114:1079-1084.
12. Davis MD, Fisher MR, Gangnon RE, et al. Risk factors for high-risk proliferative diabetic retinopathy and severe visual loss: Early Treatment Diabetic Retinopathy Study Report #18. *Invest Ophthalmol Vis Sci*. 1998;39:233-252.
13. Ferris FL, Chew EY, Hoogwerf BJ. Serum lipids and diabetic retinopathy. *Diabetes Care*. 1996;19:1291-1293.
14. Chowdhury TA, Hopkins D, Dodson PM, Vafidis GC. The role of serum lipids in exudative diabetic maculopathy: is there a place for lipid lowering therapy? *Eye*. 2002;16:689-693.
15. Lyons TJ, Jenkins AJ, Zheng D, et al. Diabetic retinopathy and serum lipoprotein subclasses in the DCCT/EDIC cohort. *Invest Ophthalmol Vis Sci*. 2004;45:910-918.
16. Ugun N, Yildirim Z, Kilic N, Gursel E. The importance of serum lipids in exudative diabetic macular edema in type 2 diabetic patients. *Ann NY Acad Sci*. 2007;1100:213-217.
17. Miljanovic B, Glynn RJ, Nathan DM, Manson JE, Schaumberg DA. A prospective study of serum lipids and risk of diabetic macular edema in type 1 diabetes. *Diabetes*. 2004;53:2883-2892.
18. Dorman TL, Carter RD, Bron AJ, Turner RC, Mann JI. Low density lipoprotein cholesterol: an association with the severity of diabetic retinopathy. *Diabetologia*. 1982;22:167-170.
19. Dodson PM, Gibson JM. Long-term follow-up of and underlying medical conditions in patients with diabetic exudative maculopathy. *Eye*. 1991;5:699-703.
20. van Leiden HA, Dekker JM, Moll AC, et al. Blood pressure, lipids, and obesity are associated with retinopathy: the Hoorn study. *Diabetes Care*. 2002;25:1320-1325.
21. Mohamed Q, Gillies M, Wong TY. Management of diabetic retinopathy: a system-

- atic review. *JAMA*. 2007;298:902–916.
22. Leung H, Wang J, Rochtchina E, et al. Dyslipidaemia and microvascular disease in the retina. *Eye*. 2005;19:861–868.
 23. Zhang J, McGwin G. Association of statin use with the risk of developing diabetic retinopathy. *Arch Ophthalmol*. 2007;125:1096–1099.
 24. Dorne PA. Exudative diabetic retinopathy. The use of clofibrate in the treatment of hard exudates using a reduced nut prolonged dosage over several years. *Am J Ophthalmol*. 1977;37:393–400.
 25. Harrold BP, Marmion VJ, Gough KR. A double-blind controlled trial of clofibrate in the treatment of diabetic retinopathy. *Diabetes*. 1969;18:285–291.
 26. Rencova E, Novak J, Saic E, Kalinova M. Objective evaluation of the success of treatment in exudative diabetic maculopathy. *Cesk Oftalmol*. 1992;48:37–41 (in Czech).
 27. Freyberger H, Schifferdecker E, Schatz H. Regression of hard exudates in diabetic background retinopathy in therapy with etofibrate antilipemic agent. *Med Klin* 1994; 89: 594–597 (in German).
 28. Cullen JF, Ireland JT, Oliver MF. A controlled trial of atromid therapy in exudative diabetic retinopathy. *Trans Am Ophthalmol Soc*. 1964;84:281–295.
 29. Duncan LJ, Cullen JF, Ireland JT, et al. A three year trial of atromid therapy and exudative diabetic retinopathy. *Diabetes*. 1968;17:458–467.
 30. The FIELD study investigators. Effects of long-term fenofibrate therapy on cardiovascular events in 9795 people with type 2 diabetes mellitus (the FIELD study): randomised controlled trial. *Lancet*. 2005;366:1849–1861.
 31. FIELD study investigators. The Fenofibrate Intervention and Event Lowering in Diabetes Study (FIELD): baseline characteristics and short-term effects of fenofibrate. *J Cardiovasc Diabetol*. 2005;4:13.
 32. ETDRS Group. Grading diabetic retinopathy from stereoscopic color fundus photographs— an extension of the modified Airlie House classification. ETDRS report number 10. *Ophthalmology*. 1991;98:786–806.
 33. Keech AC, Mitchell P, Summanen PA, et al for the FIELD study investigators. Effect of fenofibrate on the need of laser treatment for diabetic retinopathy (FIELD study): a randomised controlled trial. *Lancet*. 2007;370:1687–1697.
 34. Caldwell RB, Bartoii M, Behzadian MA, et al. Vascular endothelial growth factor and diabetic retinopathy: role of oxidative stress. *Curr Drug Targets*. 2005;6:511–524.
 35. Ferrara N. Role of vascular endothelial growth factor in regulation of physiological angiogenesis. *Am J Physiol*. 2001;280:C1358–C1366.
 36. Kim J, Ahn JH, Kim JH, et al. Fenofibrate regulates retinal endothelial cell survival through the AMPK signal transduction pathway. *Exp Eye Res*. 2007;84:886–893.
 37. Malik J, Melenovsky V, Wichterle D, et al. Both fenofibrate and atorvastatin improve vascular reactivity in combined hyperlipidemia (fenofibrate versus atorvastatin trial—FAT). *Cardiovasc Res*. 2001;52:290–298.
 38. Meleth AD, Agron E, Chan C, et al. Serum inflammatory markers in diabetic retinopathy. *Invest Ophthalmol Vis Sci*. 2005; 46:4295–4301.
 39. Rosenson RS, Wolff DA, Huskin AL, et al. Fenofibrate therapy ameliorates fasting and postprandial lipoproteinemia, oxidative stress, and the inflammatory response in subjects with hypertriglyceridemia and the metabolic syndrome. *Diabetes Care*. 2007;17:31–55.
 40. Demircan N, Safran B, Soylu M, et al. Determination of vitreous interleukin-1 (IL-1) and tumour necrosis factor (TNF) levels in proliferative diabetic retinopathy. *Eye*. 2006;20:1366–1369.
 41. Ryan KE, McCance DR, Powell L, et al. Fenofibrate and pioglitazone improve endothelial function and reduce arterial stiffness in obese glucose tolerant men. *Atherosclerosis*. 2007;194: e123–e130.
 42. Cameron AJ, Shaw JE, Zimmet PZ. The metabolic syndrome: prevalence in world-wide populations. *Endocrinol Metab Clin North Am*. 2004;33:351–375.
 43. Aiello LP, Davis MD, Girach, et al. Effect of ruboxistaurin in patients with diabetic macular edema: thirty-month results of the randomized PKC-DMES clinical trial. *Arch Ophthalmol*. 2007;125:318–324.
 44. PKC-DRS study group. The effect of ruboxistaurin on visual loss in patients with moderately severe to very severe nonproliferative diabetic retinopathy: initial results of the Protein Kinase C beta Inhibitor Diabetic Retinopathy Study (PKC-DRS) multicenter randomized clinical trial. *Diabetes*. 2005; 54:2188–2197.
 45. Aiello LP, Davis MD for the PKC-DRS2 study group. Effect of ruboxistaurin on visual loss in patients with diabetic retinopathy. *Ophthalmology*. 2006;113:2221–2230.
 46. Patel A for the ADVANCE study group. Effects of a fixed combination of perindopril and indapamide on macrovascular and microvascular outcomes in patients with type 2 diabetes mellitus (the ADVANCE trial): a randomised controlled trial. *Lancet*. 2007;370:829–840.

INSTRUCTIONS FOR CME CREDIT

CME credit is available electronically via www.dulaneyfoundation.org.

To answer these questions online and receive real-time results, please visit www.dulaneyfoundation.org and click "Online Courses." If you are experiencing problems with the online test, please e-mail us at support@dulaneyfoundation.org and explain the details of any problems you encounter with the Web site. Alternatively, you can fax your exam to us at +1 610 771 4443. Please note, in order to receive your certificate and credit when faxing your test, you must include your full name as well as an e-mail address, as certificates will be issued electronically. If you do not have an e-mail address, please include a fax number or a physical mailing address and indicate how you would like to receive your certificate (ie, fax, e-mail, physical mail). Please print clearly.

CME QUESTIONS

- 1. In the FIELD study, laser treatment for diabetic eye disease was needed more often in participants with poor glycemic control or blood pressure control than in those with good control of these factors.**
 - (a) True
 - (b) False
- 2. The primary endpoint in the ophthalmology sub-study was**
 - (a) a two-step progression of retinopathy grade
 - (b) a composite of two-step progression of retinopathy grade, macular edema, or laser treatments
 - (c) a one-step progression in retinopathy grade
 - (d) new macular edema
- 3. Which of the following is NOT TRUE with regard to FIELD patients who received laser treatment?**
 - (a) they were more likely to be male
 - (b) they had diabetes for fewer than 7 years
 - (c) they had a higher waist-to-hip ratio
 - (d) they were more likely to report microvascular complications
- 4. The effects of fenofibrate in the FIELD study can be directly attributed to an improvement in lipid profile.**
 - (a) True
 - (b) False
- 5. What percentage of patients in the ophthalmology substudy were at low risk for laser treatment?**
 - (a) 50%
 - (b) 25%
 - (c) 80%
 - (d) 75%
- 6. Fenofibrate treatment in FIELD was associated with**
 - (a) less need for laser treatment of diabetic eye disease
 - (b) less macular edema
 - (c) less diabetic retinopathy progression
 - (d) all of the above
- 7. Fenofibrate did not improve markers of diabetic control.**
 - (a) True
 - (b) False
- 8. Which of the following were discussed in terms of the pathophysiology of diabetic eye disease?**
 - (a) microvascular ischemia is the hallmark of diabetic retinopathy
 - (b) macular edema is associated with visual loss
 - (c) VEGF expression is increased
 - (d) fenofibrate may reduce inflammation
 - (e) all of the above
- 9. Fenofibrate has been shown to reduce markers of endothelial dysfunction**
 - (a) True
 - (b) False
- 10. FIELD investigators concluded:**
 - (a) fenofibrate should be considered in the management of diabetic eye disease
 - (b) fenofibrate's effects are additive with those from tight glucose and blood pressure control
 - (c) the benefit of fenofibrate was seen rapidly after treatment
 - (d) all of the above

